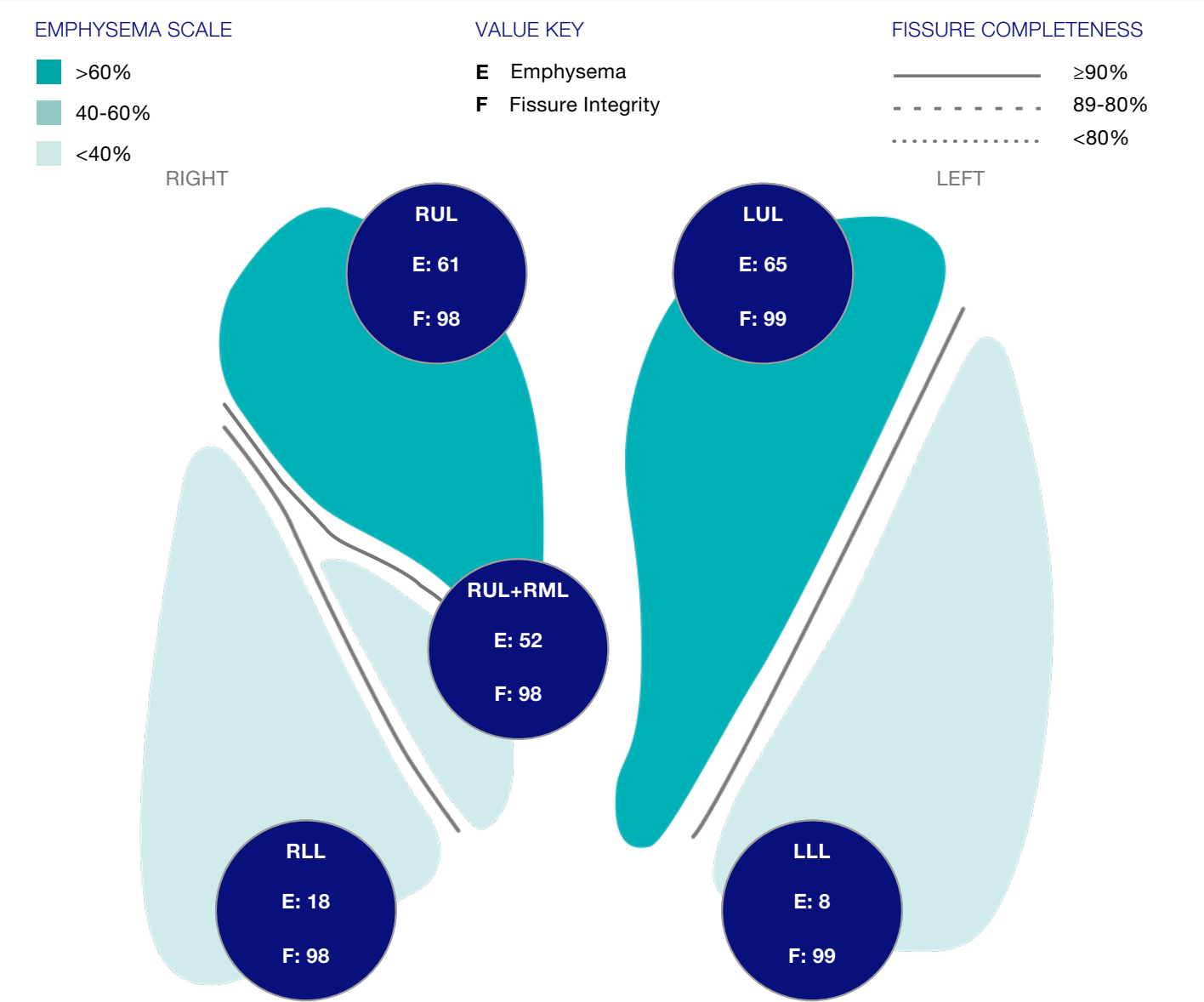


PATIENT NAME:	PATIENT ID:	SCAN ID:	STUDY DATE:	ORDER DATE:
Patient Name	82345	Unknown	October 1, 2000	June 19, 2023
KERNEL: ✓ STANDARD				



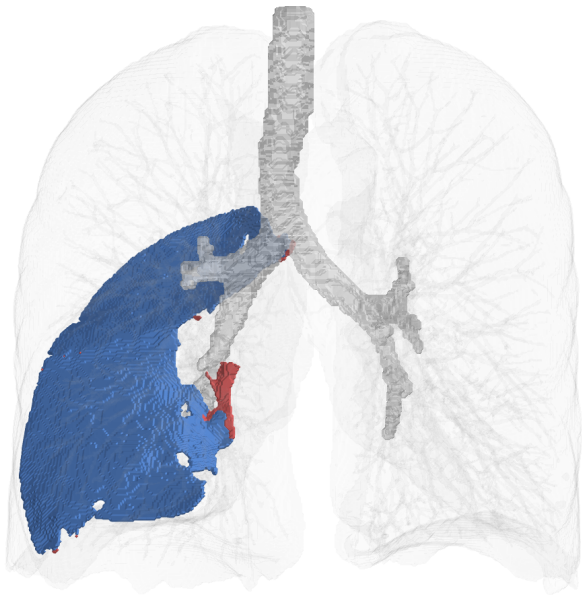
	RUL	RML	RUL+RML	RLL	LUL	LLL
EMPHYSEMA (% -920 HU)	61	23	52	18	65	8
FISSURE COMPLETENESS	98	NA	98	98	99	99
EMPHYSEMA (% -950 HU)	41	5	33	5	44	2
VOLUME	1101	316	1418	958	1432	662

Disclaimer: This report neither constitutes, nor replaces a radiological analysis. The medical and legal responsibility with respect to the diagnosis and choice of therapy remains solely with the responsible physician. Analysis by Imbio.

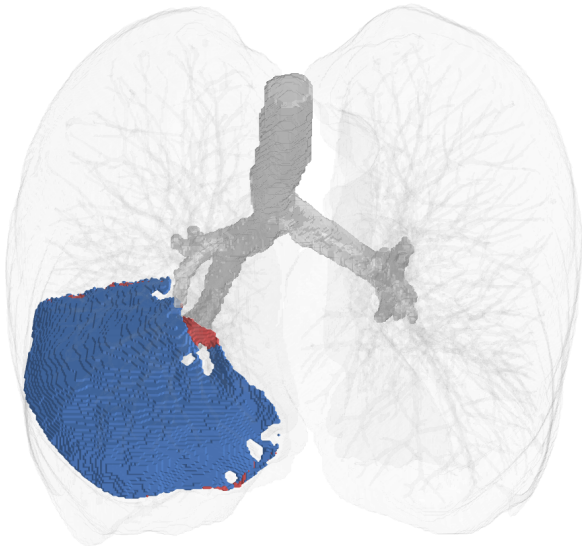
PATIENT NAME:	PATIENT ID:	SCAN ID:	STUDY DATE:	ORDER DATE:
Patient Name	82345	Unknown	October 1, 2000	June 19, 2023
KERNEL: ✓ STANDARD				

LUNG FISSURE VISUALIZATION

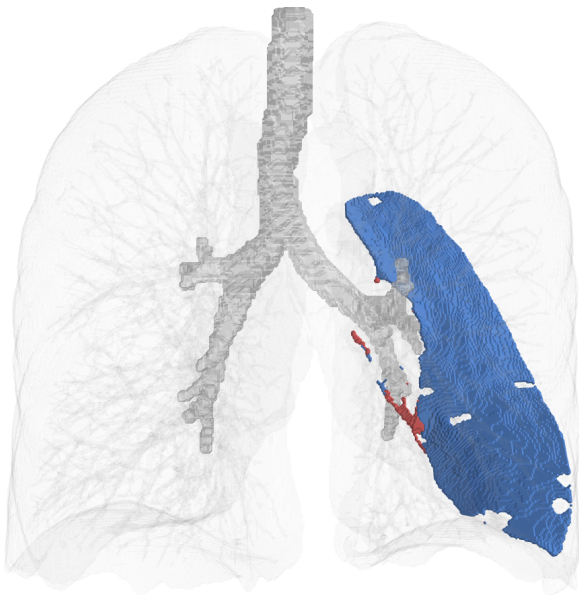
Complete Incomplete



Right Oblique Fissure  
98% Complete



Right Horizontal Fissure  
97% Complete



Left Oblique Fissure  
99% Complete

Disclaimer: This report neither constitutes, nor replaces a radiological analysis. The medical and legal responsibility with respect to the diagnosis and choice of therapy remains solely with the responsible physician. Analysis by Imbio.